

Case Report

Open Access, Volume 2

Laparoscopic Surgical Treatment of GISTs in an Emergency and Elective Regime: Literature Review and Report a Case

Dianda David¹; Perotti Bruno¹; Guelfi Riccardo¹; Corti Federico²; Gatta Luigi²; Arganini Marco¹; Bruno Perotti^{1*}

¹General Surgery Unit, Versilia Hospital, AUSL Toscana Nord-Ovest, Lido di Camaiore (LU), Italy.

²Gastroenterology Unit, Versilia Hospital, AUSL Toscana Nord-Ovest, Lido di Camaiore (LU), Italy.

Introduction

Gastrointestinal Stromal Tumors (GISTs) are the most common mesenchymal tumors of the alimentary tract; they arise from the interstitial cells of Cajal [1], pacemaker cells interposed between the smooth muscle cells of the digestive tract and intramural neurons and characterized by the over expression of tyrosine kinase receptor C-Kit [2], (CD117), a type III tyrosine kinase receptor for stem cell growth factor, were found to be the source of GISTs [3]. GISTs can associate on other mutations [5,6]: about 5% of cases are part of family genetic syndromes. The most common site of involvement is the stomach (56%), which is characterised by a better prognosis, followed by the small intestine (32%) and then the colon and rectum (6%) [1], although they can occur at any level of the digestive tract and occasionally in the omentum, mesentery and peritoneum. Most cases of GISTs are sporadic. The correct diagnosis of GIST is determined by histopathological examination and immunohistochemistry [7].

They are frequently asymptomatic and may be detected incidentally on imaging studies for other indications. In particular small size GISTs are usually asymptomatic and are diagnosed incidentally on radiological imaging for a different purpose or during an endoscopic exploration, or during surgery. Large tumors may cause abdominal distention, compression of the gastrointestinal tract (for example GISTs with exophytic growth) or obstruction of the gastrointestinal lumen (tumors with endophytic growth). Symptomatic GISTs often make patient suffer from early satiety, vague abdominal discomfort, nausea, upper GI bleeding, producing anemia and melena. Clinical manifestations are based on size

and tumor location. In the absence of complications, such as upper digestive hemorrhage/hemoperitoneum, intestinal obstruction, tumor perforation, or obstructive jaundice, the symptoms are nonspecific (anemia, early satiety, swelling, abdominal pain) [8]. The most common manifestation is gastrointestinal bleeding, accompanied by anemia, hematemesis or melena. Dysphagia is the main symptom encountered in esophageal GISTs. Furthermore, metastases can occur in advanced stages.

Suspected GISTs are usually evaluated with computed tomography (CT) and magnetic resonance imaging (MRI) scans; CT scan remains the preferred initial imaging method used for staging the disease. The lesion appear as hypervascular, heterogenous, and enhancing masses, which displace rather than invade adjacent organs. They appear as smooth submucosal elevations on upper GI endoscopy. Although endoscopy is useful to characterize and locate the lesion, biopsies rarely obtain adequate tissue to confirm the diagnosis. Endoscopic ultrasound can confirm the origin of the tumor from the submucosal layer and allow for image-guided, deep sampling. In GISTs found in specific locations (e.g., the rectum) or in evaluating the anatomical extension of surgery, MRI may be a better imaging option [9].

The survival rate of patients with GIST depends on multiple factors: recurrence after treatment, risk category, GIST stage, or treatment applied. Thus, patients with localized GISTs have a 5-year life expectancy of 93%, while patients with locally advanced GISTs have a 5-year survival rate of 80%, and those with metastatic GISTs of 55% [4]. Risk stratification of GISTs attempts to de-

Manuscript Information: Received: Nov 21, 2022; Accepted: Dec 26, 2022; Published: Dec 30, 2022

Correspondance: Dr Bruno Perotti, General Surgery Unit, Versilia Hospital, AUSL Toscana Nord-Ovest, Lido di Camaiore (LU), Italy.

Email: bruno.perotti@uslnordovest.toscana.it

Citation: David D, Bruno P, Riccardo G, Federico C, Luigi G, et al. Laparoscopic Surgical Treatment of GISTs in an Emergency and Elective Regime: Literature Review and Report A Case. *J Oncology*. 2022; 2(2): 1074.

Copyright: © Perotti B 2022. Content published in the journal follows creative common attribution license.

fine the risk of a poor outcome and to identify patients who may benefit from adjuvant therapy.

Clinically, the classification scores by Fletcher et al. And Miettinen and Lasota are the most widely accepted ones. Fletcher et al. classify the risk of aggressive evolution in four classes, depending on mitotic rate and tumor size:

- Very low risk: tumoral size <2 cm; mitotic count <5/50 high-power field;
- Low risk: tumoral size 2–5 cm; mitotic count <5/50 high-power field;
- Intermediate risk: tumoral size <5 cm and mitotic count 6–10/50 high-power field, or tumoral size 5–10 cm and mitotic count <5/50 high-power field;
- High risk: tumoral size >5 cm and mitotic count >5/50 high-power field, or tumoral size >10 cm and any mitotic rate, or any tumoral size and mitotic rate >10/50 high-power field [10].

Compared to GISTs that are localized in the small intestine or rectum, gastric localization of GISTs is associated with a better prognosis [11].

Surgical treatment

The role of minimal invasive surgery has been growing in recent years, while traditionally, open surgery has been advocated for GISTs, especially for fear of peritoneal seeding. The use of a transgastric approach avoids the potential complication of luminal stenosis following a wedge resection of a tumor close to the cardia. Local invasion is uncommon so that lymphadenectomies are rarely required: a wide local resection is usually curative. Irrespective of tumor size, a laparoscopic approach can be considered as the first line in uncomplicated GISTs [1]. Laparoscopic approach is safe and feasible for Gastric GIST both in urgent and elective settings. Laparoscopy shows a recurrence rate similar to open surgery when radical resection are performed, even for lesions greater than 5 cm. It is important to take in consideration the very surgical team experience, one of the most important factors reducing the incidence of operative complications with better long-term outcomes, both oncological and postoperative [2]. While traditionally, open surgery has been advocated for GISTs, for fear of peritoneal seeding, the role of minimal access surgery has been growing in recent years. The use of a transgastric approach avoids the potential complication of luminal stenosis following a wedge resection of a tumor close to the cardia. Because lymphadenectomies are rarely required and local invasion is uncommon, a wide local resection is usually curative. Thus, a laparoscopic approach can be considered as the first line in uncomplicated GISTs, irrespective of tumor size [1]. A wide, local resection with a 1 to 2 cm margin may be considered adequate. Additionally, a stapled wedge gastrectomy would lead to a loss of significant uninvolved gastric wall with the potential for significant luminal compromise. It has also been seen that the margin of resection does not significantly affect the outcome, with similar recurrence-free survival in patients who had R0 or R1 resections.

One potential shortcoming of transgastric approach is compromising the vascularity of the greater curvature, which can lie between two longitudinal gastric incisions. It is useful to confirm adequate vascularity of the greater curvature in patients with the use of indocyanine green (ICG) fluorescence angiography.

Histopatology

The section surface may be homogeneous, seen mostly in small-size GISTs, or heterogeneous, with areas of hemorrhage and necrosis in larger tumors. In small tumors, the coating mucosa remains unchanged (appearing normal), but in large, more aggressive tumors, it may ulcerate. There are three main types of GISTs: spindle cell type (70%), epithelioid type (20%) and mixed type (10%) [3]. These tumors may range from small, benign lesions to large, hemorrhagic and necrotic masses with metastases. Macroscopically, GISTs are well-defined, firm consistency, white in color and not encapsulated [7].

Case report

Here we report a case of a 80-year-old female patient who was being evaluated for weakness, anemia, and hematemesis.

An abdominal computed tomography (CT) confirmed the presence of a voluminous ETP-like lesion, intensely capturing contrast medium, of about 6 cm in maximum diameter, apparently originating from the submucosa of the gastric body, with extra-parietal extension at the level of the great gastric curve, and with erosion of the mucosa on the internal side. Hyperdense material is detected inside the gastric lumen as from bleeding in progress and in the arterial phase the lesion appears vascularized by a large arterial feeder starting from the A. gastric. No significant lymphadenomegaly or secondary lesions affecting the abdominal parenchymatous organs are noted. Diverticulosis of the sigmoid colon. Not free air. No versmental flaps in the abdomen. Adjust the size and course of the great abdominal vessels (ATS of the abdominal aorta). Non-pleuro - pericardial effusion." The ASA score estimated was III.

A bleeding ulcerated lesion of the gastric body was endoscopically found at the level of the posterior wall which couldn't be controlled endoscopically.

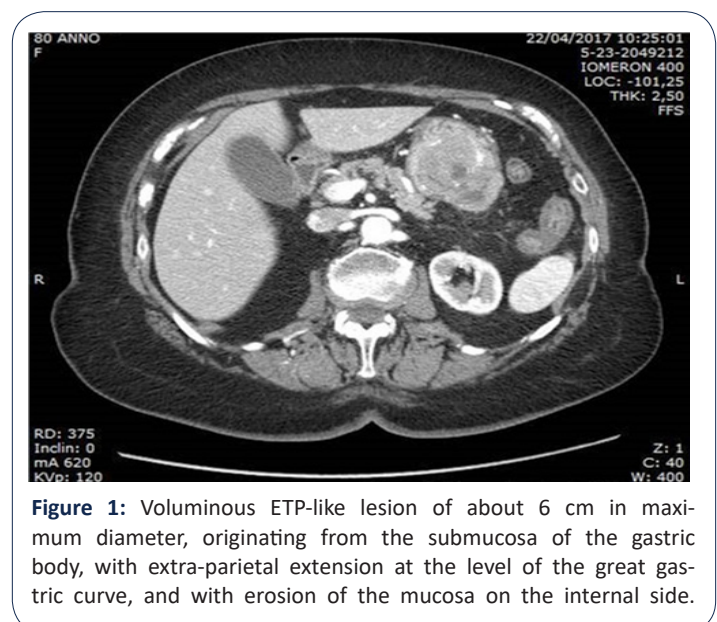


Figure 1: Voluminous ETP-like lesion of about 6 cm in maximum diameter, originating from the submucosa of the gastric body, with extra-parietal extension at the level of the great gastric curve, and with erosion of the mucosa on the internal side.

Operative steps

Laparoscopic access in the peri-umbilical site and under vision of another 3 trocars in the usual sites; negative exploration for hepatic and / or peritoneal repeats; opening of the gastrocolic ligament with Ultracision and access to the retrocavity of the epiploons, with a finding of neoformation on the posterior gastric wall (Figure 2), with a prevalent exophytic development, of about 6 cm of max diameter, facing great curvature, below the fundus. Further mobilization of the stomach: we proceed to sleeve gastrectomy including the aforementioned lesion, with endo gia (4 refills of 60) (Figure 3). Some hemostatic points on the cut, intracorporeal. Positioning of SNGs; washes, n. 1 drain; layered synthesis of 10 mm breccias.

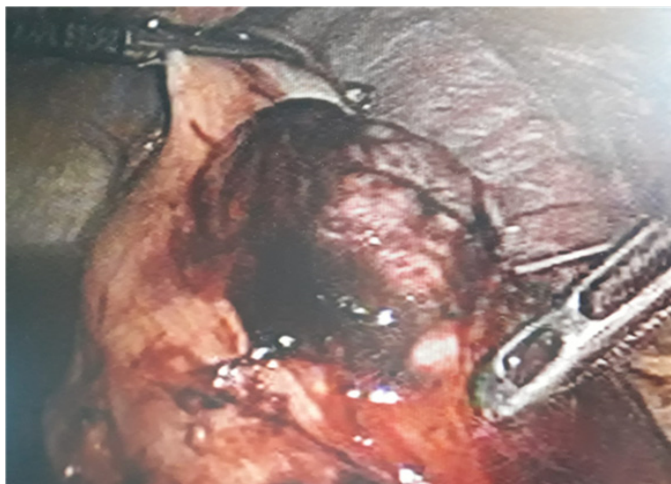

Figure 2: Neoformation on the posterior gastric wall, with a prevalent exophytic development, of about 6 cm of max diameter.

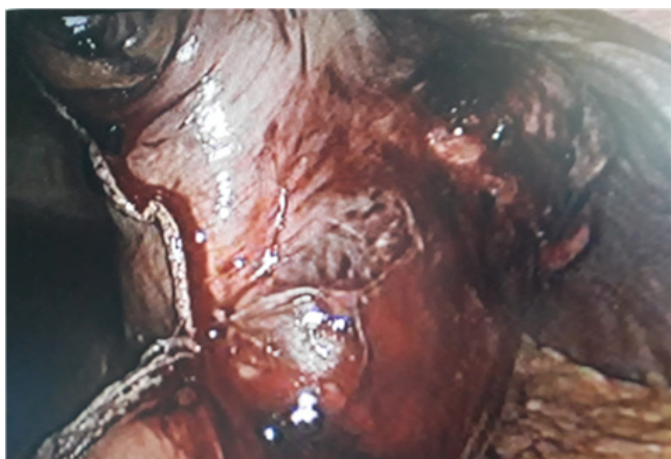

Figure 3: Sleeve gastrectomy including the aforementioned lesion, with endo gia (4 refills of 60).

The operative time was 120 minutes, and there was not significant blood loss. Postoperatively, the patient recovered well and was discharged by the eight postoperative day. To date the patient is in good health and disease free; control EGDS one year after surgery reported normal gastroresection outcomes. Anatomicopathological examination reported at the level of the submucosal tunic, a neoformation of the largest diameter (estimated after

fixation) of 5.5 cm, of a yellowish-white color, with hemorrhagic areas, duraelastic consistency, fasciculated appearance and well demarcated margins is identified. The neoformation does not ulcerate the mucous membrane, it is 0.5 cm from the surgical resection margin and is close to the serous cassock (Figure 4). At the microscopical examination, a mesenchymal neoplasm consisting mainly of epithelioid cells, which develops in the context of the gastric wall (from the submucosal to the subserosal cassock) was found, with the presence of hemorrhagic areas. Absence of necrosis, calcifications, cellular pleomorphism. Mitotic index: low (2 mitoses / 5 mm²); proliferative activity (evaluated with Ki-67%): low (2%). Surgical resection margin and deep margin unharmed. Positivity for vimentin, C-KIT (CD117), DOG-1 (ANO1), CD34 and negativity for desmin, smooth muscle actin, S100 were detected.

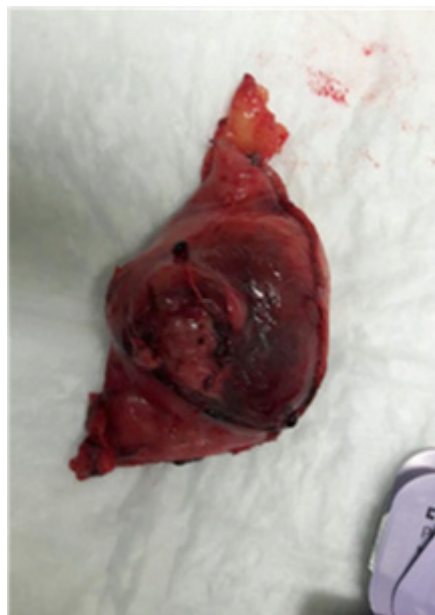

Figure 4: The neoformation does not ulcerate the mucous membrane, it is 0.5 cm from the surgical resection margin and is close to the serous cassock.

Discussion

Gastric GISTs with dimensions ≤ 4 cm can benefit from safe endoscopic resections. Gastric GISTs with dimensions >4 cm have a risk of recurrence or even metastasis, and may require adjuvant therapy with tyrosine kinase inhibitors (TKIs), or even the combination of an endoscopic and surgical technique [12].

Complete surgical resection remains the mainstay of treatment for non-metastatic GIST. It is the very only potentially curative therapy. It is now understood that all GISTs have some malignant potential, while traditionally GISTs were thought to exist on a spectrum from benign to malignant. Mitotic index and tumor size and are the two principal attributes, which help stratify malignant potential of the tumor. These tumors are good candidates for minimal access surgery, laparoscopic surgery was only considered for smaller GISTs, up until a few years ago. Studies have shown that as long as the aforementioned oncological principles are followed, laparoscopic surgery has better short-term outcomes in the view of decreased shorter hospital stay and blood loss. A recent meta-analysis showed that long-term outcomes were found to be equivalent to open surgery, even for larger GISTs.

Follow up

Although the risk of recurrence is not zero, patients at very low risk may not require postoperative follow-up. In low-risk patients, a CT scan examination is recommended every 6 months for 5 years. Intermediate–high risk patients require postoperative follow-up by CT examination at 3 months in the first 3 years, then at 6 months for 5 years, then annually. There is a consensus that abdominal ultrasonography can replace CT evaluation once a year. In patients that are undergoing TKI therapy, PET/CT is sensitive for assessing treatment response, tumor recurrence or treatment resistance [13].

Conclusion

So, minimally invasive surgery can be considered the first approach for uncomplicated cases, irrespective of their size. The combined approach both endoscopic and laparoscopic may allow a better exposure of the tumour which ensure a radical resection and has shown to be an effective technique [2]. Appropriate patient selection and advanced laparoscopic skills are critical to ensure that oncologic principles in the management of GIST of the stomach are not compromised.

References

1. Arora E, Gala J, Nanavati A, Patil A, Bhandarwar A. Laparoscopic Transgastric Resection of a Large Gastric GIST: A Case Report and Review of Literature. *Surg J (N Y)*. 2021; 7: e337-e341.
2. Di Buono G, Maienza E, Buscemi S, Bonventre G, Romano G, et al. Combined endo-laparoscopic treatment of large gastrointestinal stromal tumor of the stomach: Report of a case and literature review. *Int J Surg Case Rep*. 2020;77S: S79-S84.
3. Gheorghe G, Bacalbasa N, Ceobanu G, Ilie M, Enache V, et al. Gastrointestinal Stromal Tumors-A Mini Review. *J Pers Med*. 2021; 11: 694.
4. American Society of Clinical Oncology.
5. Nishida T, Blay JY, Hirota S, Kitagawa Y, Kang YK. The standard diagnosis, treatment, and follow-up of gastrointestinal stromal tumors based on guidelines. *Gastric Cancer*. 2016; 19: 3-14.
6. Joensuu H, Hohenberger P, Corless CL. Gastrointestinal stromal tumour. *Lancet*. 2013; 382: 973-983.
7. Fulop E, Marcu S, Milutin D, Borda A. Gastrointestinal stromal tumors: Review on morphology, diagnosis and management. *Rom J Morphol Embryol*. 2009; 50: 319-326.
8. El-Menyar A, Mekkodathil A, Al-Thani H. Diagnosis and management of gastrointestinal stromal tumors: An up-to-date literature review. *J Can Res*. 2017; 13: 889-900.
9. Scarpa M, Bertin M, Ruffolo C, Polese L, D'Amico DF, et al. A systematic review on the clinical diagnosis of gastrointestinal stromal tumors. *J Surg Oncol*. 2008; 98: 384-392.
10. Fletcher CD, Berman JJ, Corless C, Gorstein F, Lasota J, et al. Diagnosis of gastrointestinal stromal tumors: A consensus approach. *Int J Surg Pathol*. 2002; 10: 81-89.
11. Miettinen M, Lasota J. Gastrointestinal stromal tumors: Pathology and prognosis at different sites. *Semin Diagn Pathol*. 2006; 23: 70-83.
12. Zhang Y, Mao XL, Zhou XB, Yang H, Zhu LH, et al. Long-term outcomes of endoscopic resection for small (≤ 4.0 cm) gastric gastrointestinal stromal tumors originating from the muscularis propria layer. *World J Gastroenterol*. 2018; 24: 3030-3037.
13. Casali PG, Abecassis N, Aro HT, Bauer S, Biagini R, et al. Gastrointestinal stromal tumours: ESMO–EURACAN Clinical Practice Guidelines for diagnosis, treatment and follow-up†. *Ann. Oncol*. 2018; 29.