

Case Series

Open Access, Volume 3

In-Situ Follicular Neoplasia: A Case Series

Vikram Arora^{1*}; Monalisa Sur²

¹McMaster University, Hamilton, ON, Canada.

²Department of Pathology and Molecular Medicine, McMaster University and Juravinski Hospital and Cancer Centre, Hamilton, ON, Canada.

Abstract

Introduction: Precursor lymphoid lesions have long been recognized in hematopathology. Monoclonal B-cell lymphocytosis has been established as a precursor to CLL, and NK-cell enteropathy was recently identified as a lymphoproliferative disease mimicking NK/T-cell lymphoma in the digestive tract. Neither of these lesions requires treatment without transformation to a more aggressive form. Similarly, the relationships between certain lymphomas and newly described associated atypical proliferations not meeting the WHO criteria for lymphoma have recently been investigated. In particular, in-situ follicular neoplasia and in-situ mantle cell neoplasia have been identified but somewhat underdiagnosed in routine surgical practice. The former lesion is characterized by focal germinal center staining of a neoplastic follicle with BCL-2 in a background of a reactive lymph node, with otherwise preserved nodal architecture. Currently, there are no established guidelines for treating these lesions, with most authors advocating a “watchful waiting” approach.

Objectives: To report ten cases of incidental in-situ follicular neoplasia from our institution (from 2005-2011). The morphologic, immunohistochemical, and clinical significance of this diagnosis will be discussed.

Results: In the cases with pelvic lymph node dissection, one of several reactive lymph nodes showed in-situ follicular lymphoma in an otherwise reactive lymph node with no architectural effacement. The neoplastic follicles showed expression of B cell and germinal center cell markers with BCL2 staining and a low Ki67 proliferation index. The reactive follicles, in contrast, were negative for BCL2 and showed a high Ki67 proliferation index. Similar findings were noted in the inguinal and mesenteric lymph nodes of the other three patients. Staging bone marrow in these five patients was negative. To date, none of the patients have demonstrated evidence of recurrence or progression to overt lymphoma.

Conclusion: In-situ follicular neoplasia is often an incidental finding and must be differentiated from “early” follicular lymphoma. Recognition of this entity is important, as no further treatment beyond surgical excision is yet recommended. However, long-term follow-up is needed to better understand the natural history, significance and potential for malignant transformation in this group of diseases.

Keywords: *In-situ* follicular neoplasia; Lymphoma; Follicular; Lymphadenopathy.

Manuscript Information: Received: Apr 14, 2023; Accepted: May 08, 2023; Published: May 15, 2023

Correspondence: Vikram Arora, McMaster University, Hamilton, ON, Canada.

Tel: 905-536-9989; Email: arorav10@mcmaster.ca

Citation: Arora V, Sur M. *In-Situ Follicular Neoplasia: A Case Series. J Oncology. 2023; 3(1): 1089.*

Copyright: © Arora V 2023. Content published in the journal follows creative common attribution license.

Introduction

In-situ follicular neoplasia (ISFN) is the monoclonal proliferation of B cells that present with similar immunophenotypic and genetic features of follicular lymphoma but is confined to the germinal centres of lymph nodes [1]. The characteristic genetic alteration of this condition is t(14;18)(q32;q21), which is similar to conventional follicular lymphoma [2]. The concept of *in situ* is a Latin phrase meaning “on site” or “in position,” and when referring to cancer, it describes neoplastic cells that lack invasive growth and are confined to the cell of origin [3]. In selected surgically removed, reactive lymph node samples, ISFN was identified in approximately 2.8% of patients [4-6].

This condition was first described in 2002 [7]. It was detected through immunohistochemical findings and molecular clonality analysis, as there is no disruption of surrounding tissue, and the lymph node architecture is preserved [7]. In 2016, the World Health Organization recognized this condition in their new classification guidelines, along with *in situ* mantle cell neoplasia [1]. It

was considered a new condition because ISFN has a low rate of progression, whereas partial involvement by follicular lymphoma (PFL) is more likely to progress [2].

There are currently no established guidelines for the treatment of this disease. Authors primarily suggest a “wait-and-see policy” following the observance of ISFN when there is no evidence of overt lymphoma [8]. One study treated patients with PFL with local radiation therapy or rituximab and observed no remaining evidence of disease following treatment [2]. This could potentially be applied to ISFN, although more studies are needed to validate the effectiveness of these treatment options.

In this report, ten cases of incidental in-situ follicular lymphoma from our cancer care institution (from 2005-2011) are discussed. Morphological results, immunohistochemical findings, computed tomography scans, and the significance of this diagnosis will be discussed.

Case series

Table 1: Patient data for ten patients with in-situ follicular neoplasia, the primary disease they presented with, and any findings that were noted on a computed tomography (CT) scan.

Patient	Age	Sex	Presentation and primary disease	Nodes taken	CT findings
1	58	F	Intestinal adhesions (benign, post hysterectomy)	Single <i>enlarged</i> node from small bowel mesentery	No lymphadenopathy noted
2	55	F	Rectosigmoid resection (metastatic papillary serous endometrial carcinoma)	Mesenteric nodes, <i>enlarged</i> right common iliac nodes	Single right pelvic sidewall node with enlargement from 10 mm to 15 mm
3	68	F	Radical hysterectomy (mixed serous/endometrioid endometrial carcinoma)	Bilateral pelvic lymph node dissection	No lymphadenopathy noted
4	63	F	Radical hysterectomy, TAH, BSO (FIGO grade 2 endometrioid adenocarcinoma)	Bilateral pelvic lymph node dissection	No lymphadenopathy noted
5	64	M	Ruptured femoral artery aneurysm repair	<i>Enlarged</i> inguinal lymph node	No lymphadenopathy noted
6	61	F	Simple hysterectomy (TAH, BSO) with pelvic lymph node dissection for FIGO 1 Endometrial Endometrioid Adenocarcinoma	Bilateral pelvic lymph node dissection	No lymphadenopathy noted
7	52	M	Sentinel lymph node dissection for Malignant Melanoma	Axillary lymph node dissection	No lymphadenopathy noted
8	72	M	Radical Prostatectomy for Prostatic adenocarcinoma	Bilateral pelvic lymph node dissection	No lymphadenopathy noted
9	68	M	Radical Prostatectomy for Prostate adenocarcinoma	Bilateral pelvic lymph node dissection	No lymphadenopathy noted
10	55	F	Chronic Cholecystitis with cholelithiasis and lymph node around cystic duct removed	Mildly enlarged lymph node around cystic duct	No lymphadenopathy noted

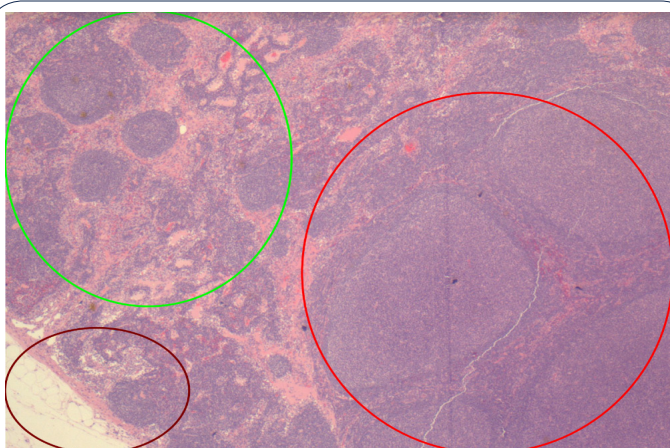


Figure 1: Hematoxylin and Eosin Stain (H&E); magnification X40.

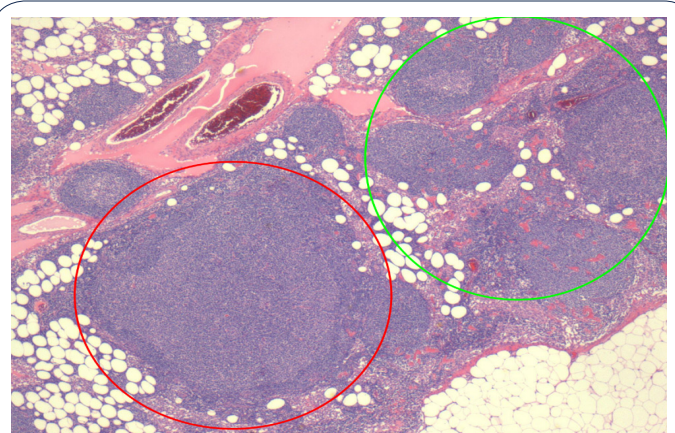


Figure 2: (H&E) magnification x100.

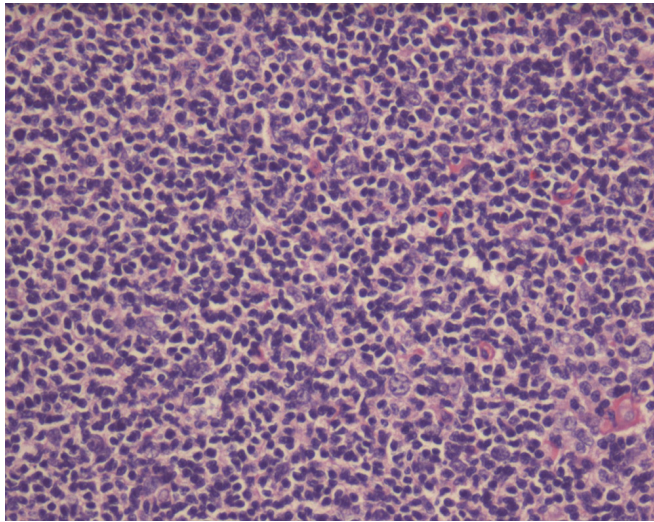


Figure 3: H&E Magnification x200.

On microscopic examination, a large, reactive follicle was identified in the site of ISFN (Figure 1). As seen in Figure 2, there is a nodular growth of neoplastic lymphoid cells that was identified. The affected follicles have a similar shape to the unreactive follicles and nodal architecture is preserved.

As seen in Figure 3, the neoplastic follicle shows no tingible body macrophages, no polarization of cells with pale and dark areas and monotonous small, cleaved cells.

As seen in Figure 4A, the cells are positive for B cell marker, CD20. Additionally, the reactive small T lymphocytes are highlighted by CD3 in Figure 4B. As seen in Figure 4C and the inset, the B cell nodules express CD10 and BCL6, which are markers for germinal centre B cells. BCL2 is an antiapoptotic protein that is typically not expressed in reactive follicles. As seen in the inset of Figure 4D, a normal follicle is negative for BCL2, whereas a follicle with ISFN shows strong BCL2 positivity. The neoplastic follicle expresses low proliferation index compared to the reactive follicle showing high proliferation index, as seen in Figure 4E.

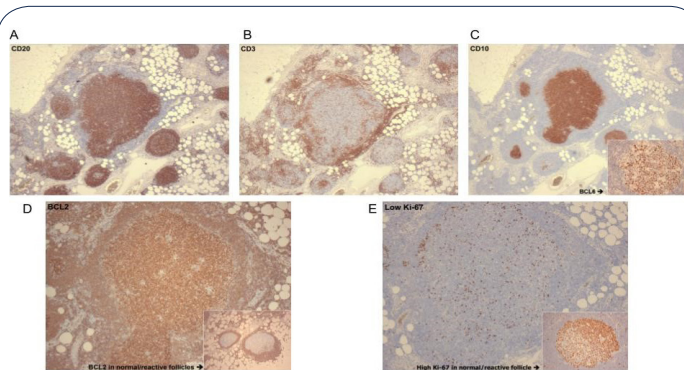


Figure 4: Immunohistochemical stains, magnification A-C (x40) and D-E (x100).

Discussion

Our case series reports ten cases of incidental in-situ follicular neoplasia. This precursor lesion was present in lymph nodes removed as part of the staging process of non-related diseases, as outlined in Table 1. This rare disease was first described in 2002 as in-situ localization of follicular lymphoma (FL) in 23 patients

and 18 with follow up [2]. In this series, five had synchronous FL at another site, three developed FL after 3, 13 and 72 months respectively and two were with no known disease with 2-96 months follow-up. This lesion is only found in 2% of reactive lymph nodes examined [2]. It is defined as partial or total colonization of germinal centers by B cells with the BCL2 translocation; t(14;18). There have been further discussions about whether a genetic hit beyond t(14;18) is required for the in-situ component to become an overt follicular lymphoma. Other case series have demonstrated similar results, a mixture of synchronous FL, subsequent FL, and no progression. Some series have reported association with subsequent non-FL lymphoma, e.g., splenic marginal zone, Hodgkin's, DLBCL [9].

The diagnosis of ISFN is typically an incidental finding. In our series, only one patient presented with lymphadenopathy on CT scans, but three patients presented with enlarged lymph nodes when extracted. The affected lymph nodes showed only partial involvement by the precursor lesion with neoplastic cells confined to the follicles admixed with reactive non-neoplastic follicles of similar appearance with preservation of normal nodal architecture. All cases presented with similar immunohistochemical staining patterns. The positive for staining for CD20, CD10 and BCL6 confirmed that these nodules were of follicular origin, and strong BCL2 of these follicles indicated the neoplastic nature of these follicles. Additionally, a low Ki-67 score further signified the low-grade nature of this lesion compared to reactive follicles, where the proliferation index is high. In all our patients, no case progressed to overt follicular lymphoma or transformed to diffuse large B cell lymphoma (DLBCL). Follow-up staging of bone marrow biopsies was negative for lymphoma.

ISFN may also indicate co-existing overt follicular lymphoma in other locations. Additionally, the lymphoma may progress with no evidence through CT scans. This highlights the importance of a long-term follow-up and observation to better understand the biological behaviour of the lymphoma. In our case series, none of the cases had concomitant or synchronous lymphomas. The lymph nodes were removed as part of the staging of unrelated diseases (Table 1).

Conclusion

In conclusion, in-situ follicular neoplasia (ISFN) is an under-recognized lesion in the field of pathology. Previously, these patients were labelled as lymphoma leading to unwarranted treatment. It is now established that these are precursor lesions. The clinical significance and natural history of this entity are still under investigation. ISFN can be detected through subtle morphologic changes noted in otherwise normal appearing follicles in a lymph node, such as monotonous small cells confined to the follicle, loss of polarization and lack of tingible body macrophages. The morphology is further supported by immunohistochemical staining of BCL2, CD10, BCL6 and low Ki-67 staining; the strong presence of these proteins restricted to the germinal centres provides evidence for ISFN. It is important that patients labelled with this diagnosis are not overtreated with chemotherapy when diagnosed with ISFN. Rather, patients should have continual hematological workups to ensure that there is no follicular lymphoma elsewhere and be observed for disease progression without any active management.

References

1. Swerdlow SH, Campo E, Pileri SA, Harris NL, Stein H, et al. The 2016 revision of the World Health Organization classification of lymphoid neoplasms. *Blood*. 2016; 127: 2375-2390.
2. Jegalian AG, Eberle FC, Pack SD, Mirvis M, Raffeld M, et al. Follicular lymphoma in situ: clinical implications and comparisons with partial involvement by follicular lymphoma. *Blood*. 2011; 118: 2976-2984.
3. Oishi N, Montes-Moreno S, Feldman AL. In situ neoplasia in lymph node pathology. *Seminars in Diagnostic Pathology*. 2018; 35: 76-83.
4. Henopp T, Quintanilla-Martínez L, Fend F, Adam P. Prevalence of follicular lymphoma in situ in consecutively analysed reactive lymph nodes: Prevalence of follicular lymphoma in situ. *Histopathology*. 2011; 59: 139-142.
5. Carvajal-Cuenca A, Sua LF, Silva NM, Pittaluga S, Royo C, et al. In situ mantle cell lymphoma: clinical implications of an incidental finding with indolent clinical behavior. *Haematologica*. 2012; 97: 270-278.
6. Bermudez G, González de Villambrosía S, Martínez-López A, Batlle A, Revert-Arce JB, et al. Incidental and Isolated Follicular Lymphoma In Situ and Mantle Cell Lymphoma In Situ Lack Clinical Significance. *American Journal of Surgical Pathology*. 2016; 40: 943-949.
7. Cong P, Raffeld M, Teruya-Feldstein J, Sorbara L, Pittaluga S, et al. In situ localization of follicular lymphoma: description and analysis by laser capture microdissection. *Blood*. 2002; 99: 3376-3382.
8. Carbone A, Santoro A. How I treat: diagnosing and managing "in situ" lymphoma. *Blood*. 2011; 117: 3954-3960.
9. Montes-Moreno S, Castro Y, Rodríguez-Pinilla SM, García JF, Mollejo M, et al. Intrafollicular neoplasia/in situ follicular lymphoma: review of a series of 13 cases. *Histopathology*. 2010; 56: 658-662.